



# Cost determinants in management of brain arteriovenous malformations

Caleb Rutledge<sup>1</sup> · Jeffrey Nelson<sup>2</sup> · Alex Lu<sup>1</sup> · Peyton Nisson<sup>3</sup> · Soren Jonzson<sup>1</sup> · Ethan A Winkler<sup>1</sup> · Daniel Cooke<sup>4</sup> · Adib A Abla<sup>1</sup> · Michael T. Lawton<sup>3</sup> · Helen Kim<sup>2</sup>

Received: 17 July 2019 / Accepted: 4 November 2019 / Published online: 23 November 2019  
© Springer-Verlag GmbH Austria, part of Springer Nature 2019

## Abstract

**Introduction** There is little data on the cost of treating brain arteriovenous malformations (AVMs). The goal of this study then is to identify cost determinants in multimodal management of brain AVMs.

**Methods** One hundred forty patients with brain AVMs prospectively enrolled in the UCSF brain AVM registry and treated between 2012 and 2015 were included in the study. Patient and AVM characteristics, treatment type, and length of stay and radiographic evidence of obliteration were collected from the registry. We then calculated the cost of all inpatient and outpatient encounters, interventions, and imaging attributable to the AVM. We used generalized linear models to test whether there was an association between patient and AVM characteristics, treatment type, and cost and length of stay. We tested whether the proportion of patients with radiographic evidence of obliteration differed between treatment modalities using Fisher's exact test.

**Results** The overall median cost of treatment and interquartile range was \$77,865 (49,566–107,448). Surgery with preoperative embolization was the costliest treatment at \$91,948 (79,914–140,600), while radiosurgery was the least at \$20,917 (13,915–35,583). In multi-predictor analyses, hemorrhage, Spetzler-Martin grade, and treatment type were significant predictors of cost. Patients who had surgery had significantly higher rates of obliteration compared with radiosurgery patients.

**Conclusions** Hemorrhage, AVM grade, and treatment modality are significant cost determinants in AVM management. Surgery with preoperative embolization was the costliest treatment and radiosurgery the least; however, surgical cases had significantly higher rates of obliteration.

**Keywords** Brain arteriovenous malformation · Cost · Cost-effectiveness

---

This article is part of the Topical Collection on *Vascular Neurosurgery - Arteriovenous malformation*

---

✉ Caleb Rutledge  
William.rutledge@ucsf.edu

- <sup>1</sup> Department of Neurological Surgery, University of California, San Francisco, San Francisco, CA, USA
- <sup>2</sup> Center for Cerebrovascular Research, Department of Anesthesia and Perioperative Care, University of California, San Francisco, San Francisco, CA, USA
- <sup>3</sup> Department of Neurological Surgery, Barrow Neurological Institute, Phoenix, AZ, USA
- <sup>4</sup> Department of Radiology and Biomedical Imaging, University of California, San Francisco, San Francisco, CA, USA

## Introduction

Brain arteriovenous malformations (AVMs) are a common cause of intracerebral hemorrhage, particularly in young people [12]. Healthcare costs and lost productivity attributable to ruptured AVMs are significant [7]. AVMs have an estimated prevalence of about 50 cases per 100,000 (95% CI 10–100) [9]. Improved access and utilization of non-invasive brain imaging have led to increased detection of unruptured AVMs.

Current management of AVMs is multimodal and includes observation or treatment with microsurgical resection, endovascular embolization, stereotactic radiosurgery, or more often some combination of them. With careful patient selection, outcomes after surgery are excellent with obliteration rates of about 96% and little morbidity and mortality [8, 11]. The Spetzler-Martin and supplementary grading systems predict surgical risks and guide patient selection for surgery. AVMs selected for surgery are routinely evaluated for

preoperative embolization to obliterate feeding artery aneurysms and deep, surgically inaccessible feeding arteries to reduce blood flow to the AVM, minimize blood loss during surgery, and reduce operative times. Curative embolization is also possible, usually in small AVMs with a single direct feeding artery [14]. Radiosurgery is a viable alternative to microsurgical resection. Delivery of a sufficient dose of radiation to the AVM induces closure of the lumen of AVM vessels and obliteration of the AVM over a 2–3-year latency period. Outcomes are also excellent with low morbidity, particularly for small AVMs [4–6, 13].

There is an increasing body of research addressing the cost of neurosurgical procedures, but there are few studies on cost determinants in the management of AVMs. The goal of this study then is to examine the association between patient and AVM characteristics and cost in brain AVMs.

## Methods

### Study population

The study was approved by the University of California San Francisco Committee on Human Research and conducted in compliance with Health Insurance Portability and Accountability Act regulations. All patients with brain AVMs at UCSF are enrolled prospectively in a brain AVM registry. Patients with AVMs who were treated with surgery, surgery with preoperative embolization, and radiosurgery between 2012 and 2015 were included in the study. Few patients were treated with embolization alone or other combinations of surgery, embolization, and radiosurgery and were excluded from this analysis. We collected the following additional variables: patient age and gender, presentation with hemorrhage, Spetzler-Martin grade, length of stay, and radiographic evidence of AVM of obliteration. Cost data was obtained from our hospital's internal accounting database and adjusted for inflation based on CPI from the Bureau for Labor Statistics using the "medical care" item to convert to 2015-adjusted dollars. Total cost reported in US dollars (\$) includes costs for inpatient and outpatient encounters, interventions, and imaging attributable to the AVM.

### Statistical analysis

Patient and AVM characteristics were summarized by treatment type as counts and percentage or means and standard deviations. We tested whether treatment type was associated with patient and AVM characteristics with Fisher's exact test or ANOVA. Costs were summarized by treatment type as medians with interquartile ranges. We used a multi-predictor generalized linear model (GLM) to determine whether there was an association between cost and the following predictors:

treatment type, age at treatment, sex, Spetzler-Martin grade, hemorrhage prior to treatment, and treatment year. Models assume gamma-distributed outcomes and a log link function, allowing us to interpret results as proportional increases (PI) adjusted for covariates. A PI less than one indicates a decrease. Similarly, we used a GLM to determine whether length of stay (LOS) was associated with the same predictors. LOS analysis excluded radiosurgery patients because their LOS was zero days. Some observations were missing Spetzler-Martin grade data and, consequently, were not included in the GLMs. We tested whether the proportion of AVMs with radiographic evidence of obliteration on follow-up imaging differed between modalities using Fisher's exact test. For radiosurgery patients, we calculated the median time to evidence of obliteration using the Kaplan-Meier survival analysis. Data analysis was conducted using Stata 15.1 SE (College Station, TX; StataCorp LLC.).

## Results

### Patient demographics

One hundred forty patients with brain AVMs underwent treatment at UCSF between 2012 and 2015 and were included in the study. The mean age at presentation and standard deviation was  $37.4 \pm 18.8$  years, 56% (78/140) were female, and 47% (66/140) presented with hemorrhage. There were 32 (27%) Spetzler-Martin grade I, 50 (42%) grade II, 23 (19%) grade III, 11 (9%) grade IV, and 3 (3%) grade V AVMs. Patients were treated with surgery alone ( $n = 74$ , 53%), surgery with preoperative embolization ( $n = 49$ , 35%), or radiosurgery alone ( $n = 17$ , 12%).

### Association between patient and AVM characteristics and treatment

Summary statistics by treatment type are presented in Table 1. Age and gender had no association with treatment type; however, hemorrhage and AVM grade were significant predictors of treatment type. Ruptured cases comprised 61% of surgery cases, but only 33% of surgery with preoperative embolization cases and 29% of radiosurgery cases ( $p = 0.003$ ). Spetzler-Martin grade was also associated with treatment type ( $p = 0.019$ ), as higher grades were more frequently treated with radiosurgery.

### Cost according to treatment modality

A summary of cost by treatment type is provided in Table 2. The overall median cost of treatment and interquartile range was \$77,865 (\$49,566–\$107,448). Surgery with embolization was the most expensive with a cost of \$91,948

**Table 1** Summary statistics by treatment type

Characteristic	Surgery only ( <i>n</i> = 74)	Surgery and embolization ( <i>n</i> = 49)	SRS only ( <i>n</i> = 17)	Overall ( <i>n</i> = 140)	<i>p</i> value
Age, years	37.5 ± 20.0	38.0 ± 17.0	35.3 ± 19.6	37.4 ± 18.8	0.874
Female	38 (51%)	32 (65%)	8 (47%)	78 (56%)	0.239
Spetzler-Martin grade					0.002
1	22/60 (37%)	7/44 (16%)	3/15 (20%)	32/119 (27%)	
2	22/60 (37%)	26/44 (59%)	2/15 (13%)	50/119 (42%)	
3	12/60 (20%)	6/44 (14%)	5/15 (33%)	23/119 (19%)	
4	3/60 (5%)	5/44 (11%)	3/15 (20%)	11/119 (9%)	
5	1/60 (2%)	0/44 (0%)	2/15 (13%)	3/119 (3%)	
Hemorrhage at presentation	45 (61%)	16 (33%)	5 (29%)	66 (47%)	0.003

Values are mean ± standard deviation, *n* (%), or *n*/total (%) when missing data is present

(\$79,914–\$140,600), while radiosurgery was the least costly at \$20,917 (\$13,915–\$35,583). Surgery alone cost \$74,540 (50,105–108,596). The least costly treatment observed was a radiosurgery case that totaled \$11,635, while the costliest was a surgical case with embolization that cost \$439,349.

### Length of hospital stay according to treatment modality

The median length of stay was 7 days (4–11). Preoperative embolization led to a slightly higher median length of stay at 8 days (6–12). In all instances, radiosurgery cases did not require hospital stays beyond their procedure.

### Multi-predictor models

Table 3 shows the results of the GLM analyses. A total of 119 observations were included in the GLM cost analysis. We found that surgery with preoperative embolization costs about 40% more than surgery alone (PI = 1.40; 95% CI, 1.10–1.79; *p* = 0.007), and radiosurgery was about 74% cheaper than surgery alone (PI = 0.26; 95% CI, 0.18–0.38; *p* < 0.001). Each point increase in Spetzler-Martin grade was associated with increased cost (PI = 1.18; 95% CI, 1.05–1.31; *p* = 0.004). Cases that presented with a hemorrhage were more costly (PI = 1.42; 95% CI, 1.11–1.82; *p* = 0.005).

A total of 104 observations were included in the GLM LOS analysis. We found that surgery with preoperative

embolization had 33% longer LOS than surgery alone (PI = 1.33; 95% CI, 1.00–1.77; *p* = 0.050). Older patients tended to have longer LOS (PI = 1.12 per decade increase; 95% CI, 1.04–1.20; *p* = 0.004). Higher Spetzler-Martin grade was associated with longer LOS (PI = 1.35; 95% CI, 1.16–1.57; *p* < 0.001), as was hemorrhage at presentation (PI = 1.51; 95% CI, 1.12–2.03; *p* = 0.007).

### AVM obliteration by treatment modality

A total of 132 observations had post-treatment imaging. The proportion of AVMs with radiographic evidence of obliteration varied by treatment modality (*p* < 0.001). All but one AVM (118 of 119, 99%) in the embolization and surgery and surgery only groups was obliterated. By contrast, 9 of 13 (69%) AVMs treated with radiosurgery had evidence of obliteration on post-treatment imaging, with a median time to imaging of 3.33 years. The median time to evidence of obliteration of radiosurgery-treated AVMs was 3.68 years (95% CI, 2.96–4.45; see Fig. 1).

### Discussion

Management of brain AVMs has evolved with advances in treatment. The current management of brain AVMs is multi-modal and includes observation or treatment with microsurgical resection, endovascular embolization, and/or stereotactic

**Table 2** Outcome summary by treatment type and overall

Group	<i>n</i>	Cost (\$)	Length of stay (days)
Surgery only	74	74,540 (50,105–108,596)	7 (5–12)
Surgery and embolization	49	91,948 (79,914–140,600)	8 (6–12)
SRS only	17	20,917 (13,915–35,583)	0 (0–0)
Overall	140	77,865 (49,566–107,448)	7 (4–11)

Cost and length of stay are summarized as median (interquartile range)

**Table 3:** Generalized linear model results

Characteristic	Treatment cost outcome			Length of stay outcome		
	PI	95% CI	<i>p</i> value	PI	95% CI	<i>p</i> value
Treatment type						
Surgery only (reference)	---	---	---	---	---	---
Embolization and surgery	1.40	(1.10, 1.79)	0.007	1.33	(1.00, 1.77)	0.050
SRS only	0.26	(0.18, 0.38)	< 0.001	---	---	---
Age (per decade increase)	1.01	(0.95, 1.07)	0.825	1.12	(1.04, 1.20)	0.004
Female	1.08	(0.86, 1.37)	0.502	1.19	(0.89, 1.60)	0.238
Spetzler-Martin grade	1.18	(1.05, 1.31)	0.004	1.35	(1.16, 1.57)	< 0.001
Hemorrhage at presentation	1.42	(1.11, 1.82)	0.005	1.51	(1.12, 2.03)	0.007

PI, proportional increase; CI, confidence interval

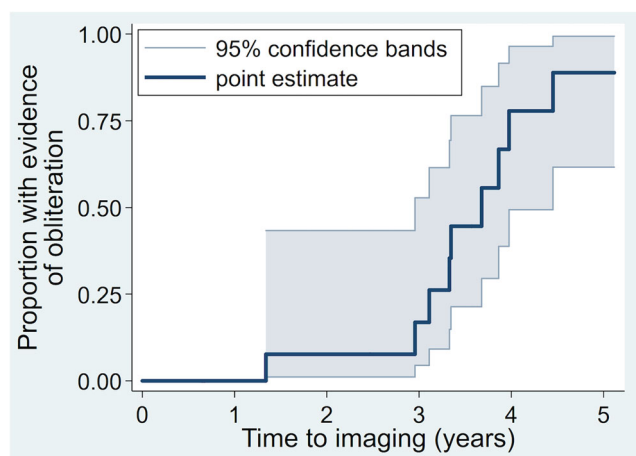
radiosurgery. Using a nationwide inpatient sample analysis, Davies et al. found that charges associated with treatment of brain AVMs have increased dramatically with the advent of multimodality treatment and a trend toward more resource-intensive therapy [3]. However, there are few recent studies examining the relative cost of different treatment modalities. Previously, Caruso et al. found radiosurgery is about 40% of the cost of open surgery [2]. Berman et al. found preoperative embolization is associated with higher cost and that higher grade is associated with higher cost, as well as a longer length of stay [1]. Our study reviewed cost determinants in multimodality management of brain AVMs in a recent series.

Consistent with prior reports, we found that surgery with embolization was the costliest treatment (\$91,948 (79,914–140,600)). Radiosurgery was far less costly (\$20,917 (13,915–35,583)). Not surprisingly, in multi-predictor analyses, hemorrhage, Spetzler-Martin grade, and treatment type were each significant independent predictors of cost. Hemorrhaged cases had 50% longer hospital stays. Each point increase in Spetzler-Martin grade increased the length of stay

by 35%. Embolized cases had 33% longer length of stay, contributing to increased costs, and also incurred charges related to the embolization procedure and embolic material. Results from cost and LOS analyses were quite similar, which is not surprising given a high degree of correlation between the outcomes (Spearman's rho = 0.83,  $p < 0.001$ ).

As expected, surgical cases with or without preoperative embolization had significantly higher rates of AVM obliteration compared with radiosurgery cases. While radiosurgery was the least costly treatment, it may not be cost-effective due to lower obliteration rates and hemorrhages during the latency period. In a study of small, operable AVMs, Porter et al. found that open surgery was in fact more cost-effective than radiosurgery for small AVMs [10]. Furthermore, while preoperative embolization followed by surgery is the costliest treatment, reducing blood loss and operative times may render it the most cost-effective. Few patients in our cohort were treated with curative embolization or other combinations of surgery, embolization, and radiosurgery and were not included in the study; however, management of brain AVMs continues to evolve with advances in endovascular techniques, microcatheter systems, Onyx, and other liquid embolysates.

While we have evaluated the direct costs of different AVM treatments and identified predictors of cost, our study does not include functional outcomes, indirect costs related to productivity losses, and quality of life measures. These should be included in future cost-effectiveness analyses. Further, our cost findings are from a single US academic hospital, which may not be generalizable to all hospitals treating AVMs, but should be representative of other high-volume academic referral centers. For example, at one major US academic center, Berman et al. reported the average cost for embolization and surgery was  $\$78,400 \pm \$4900$  versus  $\$49,300 \pm \$5800$  for surgery alone [1]. More recently, at another US center, Caruso et al. reported average costs for open surgery and radiosurgery of  $\$78,332$  and  $\$46,293$ , respectively [2]. We did find differences in costs between US and non-US centers.



**Fig. 1** Time to AVM obliteration after radiosurgery

In Canada, Porter et al. reported costs of C\$15,850 and C\$4184 for surgery and radiosurgery, respectively [10]. In the Scottish Intracranial Vascular Malformation Study, the least expensive and most common intervention was embolization alone (£16,938), while surgery alone (£18,699) and radiosurgery alone (£18,008) were similar in cost [7]. In Germany, Wellis et al. examined treatment costs of microsurgically treated patients harboring an AVM potentially amenable to radiosurgery and found the primary costs of microsurgery (€15,242) exceeded the costs of radiosurgery (€7920) twofold [15].

## Conclusions

Hemorrhage, AVM grade, and treatment modality are significant cost determinants in AVM management. Surgery with embolization was the costliest treatment and radiosurgery the least. Surgical cases regardless of preoperative embolization had significantly higher rates of AVM obliteration compared with radiosurgery.

## Compliance with ethical standards

The study was approved by the University of California San Francisco Committee on Human Research and conducted in compliance with Health Insurance Portability and Accountability Act regulations.

**Conflict of interest** The authors declare that they have no conflict of interest.

For this retrospective study, formal consent is not required

## References

- Berman MF, Hartmann A, Mast H, Sciacca RR, Mohr JP, Pile-Spellman J, Young WL (1999) Determinants of resource utilization in the treatment of brain arteriovenous malformations. *AJNR American journal of neuroradiology* 20:2004–2008
- Caruso JP, Moosa S, Fezeu F, Ramesh A, Sheehan JP (2015) A cost comparative study of Gamma Knife radiosurgery versus open surgery for intracranial pathology. *Journal of clinical neuroscience : official journal of the Neurosurgical Society of Australasia* 22:184–188. <https://doi.org/10.1016/j.jocn.2014.08.012>
- Davies JM, Yanamadala V, Lawton MT (2012) Comparative effectiveness of treatments for cerebral arteriovenous malformations: trends in nationwide outcomes from 2000 to 2009. *Neurosurgical focus* 33:E11. <https://doi.org/10.3171/2012.5.focus12107>
- Kano H, Flickinger JC, Yang HC, Flannery TJ, Tonetti D, Niranjana A, Lunsford LD (2014) Stereotactic radiosurgery for Spetzler-Martin grade III arteriovenous malformations. *Journal of neurosurgery* 120:973–981. <https://doi.org/10.3171/2013.12.jns131600>
- Kano H, Lunsford LD, Flickinger JC, Yang HC, Flannery TJ, Awan NR, Niranjana A, Novotny J Jr, Kondziolka D (2012) Stereotactic radiosurgery for arteriovenous malformations, Part 1: management of Spetzler-Martin grade I and II arteriovenous malformations. *Journal of neurosurgery* 116:11–20. <https://doi.org/10.3171/2011.9.jns101740>
- Lunsford LD, Kondziolka D, Flickinger JC, Bissonette DJ, Jungreis CA, Maitz AH, Horton JA, Coffey RJ (1991) Stereotactic radiosurgery for arteriovenous malformations of the brain. *Journal of neurosurgery* 75:512–524. <https://doi.org/10.3171/jns.1991.75.4.0512>
- Miller CE, Quayyum Z, McNamee P, Al-Shahi Salman R (2009) Economic burden of intracranial vascular malformations in adults: prospective population-based study. *Stroke; a journal of cerebral circulation* 40:1973–1979. <https://doi.org/10.1161/strokeaha.108.539528>
- Morgan MK, Rochford AM, Tsachtsaris A, Little N, Faulder KC (2004) Surgical risks associated with the management of grade I and II brain arteriovenous malformations. *Neurosurgery* 54:832–837 discussion 837–839
- Morris Z, Whiteley WN, Longstreth WT Jr, Weber F, Lee YC, Tsushima Y, Alphas H, Ladd SC, Warlow C, Wardlaw JM, Al-Shahi Salman R (2009) Incidental findings on brain magnetic resonance imaging: systematic review and meta-analysis. *BMJ (Clinical research ed)* 339:b3016. <https://doi.org/10.1136/bmj.b3016>
- Porter PJ, Shin AY, Detsky AS, Lefaive L, Wallace MC (1997) Surgery versus stereotactic radiosurgery for small, operable cerebral arteriovenous malformations: a clinical and cost comparison. *Neurosurgery* 41:757–764 discussion 764–756
- Potts MB, Lau D, Abla AA, Kim H, Young WL, Lawton MT (2015) Current surgical results with low-grade brain arteriovenous malformations. *Journal of neurosurgery*:1–9. <https://doi.org/10.3171/2014.12.jns14938>
- Ruiz-Sandoval JL, Cantu C, Barinagarrementeria F (1999) Intracerebral hemorrhage in young people: analysis of risk factors, location, causes, and prognosis. *Stroke; a journal of cerebral circulation* 30:537–541
- Steiner L, Lindquist C, Adler JR, Torner JC, Alves W, Steiner M (1992) Clinical outcome of radiosurgery for cerebral arteriovenous malformations. *Journal of neurosurgery* 77:1–8. <https://doi.org/10.3171/jns.1992.77.1.0001>
- van Rooij WJ, Jacobs S, Sluzewski M, van der Pol B, Beute GN, Sprengers ME (2012) Curative embolization of brain arteriovenous malformations with onyx: patient selection, embolization technique, and results. *AJNR American journal of neuroradiology* 33:1299–1304. <https://doi.org/10.3174/ajnr.A2947>
- Wellis G, Nagel R, Vollmar C, Steiger HJ (2003) Direct costs of microsurgical management of radiosurgically amenable intracranial pathology in Germany: an analysis of meningiomas, acoustic neuromas, metastases and arteriovenous malformations of less than 3 cm in diameter. *Acta neurochirurgica* 145:249–255. <https://doi.org/10.1007/s00701-003-0007-4>

**Publisher's note** Springer Nature remains neutral with regard to jurisdictional claims in published maps and institutional affiliations.

Reproduced with permission of copyright owner. Further reproduction prohibited without permission.